[UCI]I804:48009-200000364416

의 학 석 사 학위논문

복강경 이용 자궁선근증 절제와 복강경 혹은 개복을 통한 자궁선근증 절제술의 비교

Minimally Invasive Adenomyomectomy via Laparoscopic assisted Approach Compared with Laparoscopic or Laparotomic Approach

울 산 대 학 교 대 학 원
의 학 과
유 슬 기

복강경 이용 자궁선근증 절제와 복강경 혹은 개복을 통한 자궁선근증 절제술의 비교

지 도 교 수 노 현 진

이 논문을 의학석사 학위논문으로 제출함

2021년 2월

울 산 대 학 교 대 학 원
의 학 과
유 슬 기

유슬기의 의학석사 학위논문을 인준함

심사위원 노 현 진 (인)

심사위원 안 준 우 (인)

심사위원 이 상 훈 (인)

울 산 대 학 교 대 학 원

2021년 2월

Abstract

Minimally Invasive Adenomyomectomy via Laparoscopic assisted Approach Compared with Laparoscopic or Laparotomic Approach

Seul Gi You, M.D.

Department of Obstetrics and Gynecology,
Graduate School, University of Ulsan
(Directed by Prof. Hyun Jin Roh, M.D., Ph.D.)

Objective: To assess the safety and benefit of laparoscopic assisted adenomyomectomy compared with laparoscopic or laparotomic adenomyomectomy.

Materials and methods

This is a retrospective comparative study. Between January 2016 and January 2019 at the Department of obstetrics and Gynecology, Ulsan University Hospital, total 277 patients underwent adenomyomectomy, of which 25 had laparoscopic assisted adenomyomectomy, 82 with laparoscopic adenomyomectomy, and 170 with laparotomic adenomyomectomy laparoscopic assisted adenomyomectomy was consisted of laparoscopic uterine artery procedures for reducing blood loss and minimally incisional laparotomic adenomyomectomy. Also, additional laparoscopic surgery was performed

about possible pelvic pathology.

Results: Data on patient demographics, surgical indications, operative times, estimated blood loss (EBL), short-term complications, and postoperative hospital stays were compared. The laparoscopic assisted surgery(LAS) and laparotomic groups were comparable in terms of the average EBL (208.0±128.8 vs. 193.6±193.0 mL, p=0.11), weight of removed mass (85.5±71.7 vs. 108.2±91.9 g, p=0.39), and postoperative hospital days (HDs) (4.5±1.0 vs. 4.7±0.8 days, p=0.27). These values were lower in the laparoscopic group (EBL 119.5±79.6 ml, mass weight 39.3±25.9 g, HD 3.6±0.8 days). Additional procedures, including myomectomy and combined severe endometriosis surgery, were more frequently performed in the LAS group than in the laparotomic group. The mean operating time was longer in the LAS group (179.8±36.6 min) than in the other groups (laparoscopy 99.9±40.6 min, p<0.00; laparotomy 133.0±41.1 min, p<0.00). The three groups did not differ significantly in terms of transfusion rates, hemoglobin changes, or perioperative complications; however, febrile morbidity was lower in the laparoscopic group than in the LAS and laparotomic group.

Conclusion: LAS adenomyomectomy allows for maximal debulking of adenomyosis via extracorporeal and intracorporeal procedures, while retaining the advantages of the laparoscopic approach. With this approach, additional pelvic surgery for benign uterine and adnexal pathology can easily be performed.

Key words: Adenomyosis; laparoscopic assisted surgery; Minimally invasive surgery

차 례

List of Tables

List of Figures

Introduction

Adenomyosis is defined by the presence of endometrial gland tissue in the myometrium [1]. Adenomyosis is associated with symptoms including heavy menstrual bleeding, pelvic pain, menstrual pain and fertility issues in premenopausal women [2]. The definitive treatment of adenomyosis is hysterectomy, but for patients who prefer uterine preservation, laparotomic adenomyomectomy is considered an alternative treatment. Laparoscopic surgery is considered useful for focal adenomyosis [3]; however, in contrast to that of myoma, the margin of adenomyosis is difficult to distinguish from the normal myometrium, which is why maximal debulking of adenomyosis is performed under direct palpation. During surgery, reduction of blood loss is also important for visualization of operation field and patients' recovery after surgery. So uterine artery procedures have been attempted such as transient uterine artery occlusion (TOUA) or bilateral uterine artery ligation (BUAL). Additionally, delicate suturing is needed after adenomyosis resection; therefore, laparotomic adenomyomectomy is preferable to laparoscopic adenomyomectomy [4]. However, with the laparotomic approach, it is difficult to expose the operation field, including the lateral pelvic walls or posterior cul-de-sac (PCDS), which need to be secured for adhesiolysis, adnexal surgery or uterine vessel procedures.

LAS is a unique surgical approach that is a combination of laparoscopic and laparotomic surgery through the suprapubic incision site. It has the advantages of both laparoscopic and laparotomic surgery. The laparoscopic approach in LAS adenomyomectomy offers a laparoscopic pelvic operation field, which provides more convenient access to the lateral pelvic walls and PCDS than laparotomic adenomyomectomy to allow better uterine artery procedures and adhesiolysis. Moreover, extracorporeal operation using

the suprapubic incision allows for delicate handling of elements of the main operation including the uterine incision, adenomyosis resection, suturing, and bleeding control.

In the present study, we performed adenomyomectomy using LAS and attempted to evaluate the feasibility and benefit of LAS compared to laparoscopic and laparotomic adenomyomectomy.

Materials and methods

Patients

This is a retrospective comparative study. We reviewed the data of women who were diagnosed with adenomyosis by pathologic reports and underwent uterine conservation adenomyomectomy, between January 2016 and January 2019 at the Department of obstetrics and Gynaecology, Ulsan University Hospital. A total 277 patients underwent adenomyomectomy, of which 25 had LAS adenomyomectomy, 82 with laparoscopic adenomyomectomy, and 170 with laparotomic adenomyomectomy. These adenomyomectomy surgeries were performed for patients who had refractory symptoms of adenomyosis and who desired uterine and/or fertility preservation. Preoperatively, the adenomyosis mainly diagnosed with transvaginal ultrasonography, and after surgery, pathological records confirmed the diagnosis. All patients were selected via review of electronic medical records. This study was approved by the institutional review board of Ulsan University Hospital, No. 2019-11-025, on January 2020. Most LAS surgeries were combined with bilateral uterine artery ligation (72%) or transient occlusion of the uterine artery (20%).

Surgical techniques

For the LAS approach, a horizontal mini-laparotomic incision (approximately 5 cm, range 4-6cm) was made on 2 fingers above the symphysis pubis. A medium-sized Surgitractor ^{R} (Surgicore, Gwangju, Republic of Korea) was inserted through the extended wound. After making pneumoperitoneum by carbon dioxide via the suprapubic

area, peritoneal adhesion was checked. Then, 5-mm trocars were inserted into the umbilicus, left lower quadrant (anti-McBurney's point), and added right lower quadrant(McBurney's point), if it needed. (Fig. 1). We inspected the pelvic cavity first; if there was adhesion between the adnexa, uterus, PCDS and peritoneum, adhesiolysis was performed. If there was adnexal pathology (including endometrioma), adnexal surgery was performed (Fig. 2). Then, uterine artery manipulation, such as BUAL or TOUA, was performed using a laparoscopic approach (Fig. 3). After all these procedures, extracorporeal adenomyomectomy was performed with piecemeal resection using a scalpel through suprapubic incision (LAS site) under palpation and inspection. While mass resection ended, the whole uterus was exteriorized (Fig. 4). Bleeding control was performed by electrocoagulation and suturing. The endometrium, myometrium and serosa were repaired by 1-0 polysorb interrupted sutures to prevent dead space in the remaining myometrium. The uterus was returned to the peritoneal cavity after uterine remodeling. In the laparoscopic approach, the operation sites (including the uterus and combined surgical sites), bleeding control and irrigation were rechecked (Fig. 5).

Statistical analysis

Statistical evaluations were performed using SPSS version 24.0 (SPAA Inc., Chicago, IL, USA). Data are expressed as the mean ± standard deviation (SD) or absolute number (n) and percentage (%). The surgical outcomes between groups (laparoscopic adenomyomectomy and LAS adenomyomectomy; laparotomic adenomyomectomy and LAS adenomyomectomy) were compared using the chi-squared test or Fisher's exact tests or Mann-Whitney U test. A p value less than 0.05 was considered statistically significant.

Results

LAS was compared with laparoscopic and laparotomic adenomyomectomy with or without TOUA or BUAL. Twenty-five patients underwent LAS adenomyomectomy. A total of 82 patients who underwent laparoscopic adenomyomectomy and 170 patients who underwent laparotomic adenomyomectomy were compared.

Regarding the patient demographics, except for parity, there were no differences between the LAS, laparoscopic and laparotomic groups, as shown in Table 1. Table 2 shows the detailed disease characteristics. Intraoperative outcomes are shown in Table 3. The LAS adenomyomectomy group had the highest percentage of combined surgery (68%). Additionally, severe endometriosis (EMS) surgery (EMS stage 3-4) was more frequently performed in the LAS group (p=0.01 with laparoscopic group, p=0.04 with laparotomic group). Furthermore, myomectomy was more frequently performed in the LAS group than in the laparotomic group (p=0.04).

The LAS group and laparotomic group had similar levels of estimated blood loss (208.0±128.8 ml vs. 193.6±193.0, p=0.11, Table 3), but the laparoscopic group had less blood loss (119.5±79.6 ml, p=0.01) than the LAS group. However, there were no significant differences in the intra- and postoperative transfusion rates or even hemoglobin changes between preoperative and postoperative day 1 (1.8±1.2 in LAS, 1.7±0.9 in laparoscopic, 2.2±1.1 in laparotomic group, Table 4). The mean operating time was significantly longer in the LAS group (179.8±36.6 min, Table 3) than in the other groups (99.9±40.6 in the laparoscopic group and 133.0±41.1 in the laparotomic group). The removed adenomyosis weights were similar between the LAS and laparotomic groups (85.5±71.7 vs. 108.2±91.9 g, p=0.39, Table 3); however, the weight was heavier in the LAS group than in the laparoscopic group (p=0.00).

The postoperative outcomes are presented in Table 4. The postoperative hospital days were similar between the LAS and laparotomic groups (4.5±1.0 vs. 4.7±0.8 days) but shorter in the laparoscopic group (3.6±0.8 days). Febrile morbidity defined body temperature ≥ 37.8℃ during hospitalization was lower in the laparoscopic group than in the LAS group (p=0.00), and the laparotomic group had similar febrile morbidity to that of the LAS group (p=0.26).

Three cases of intraoperative complications were reported in the laparotomic group: 2 cases of uterine vein injury and 1 case of infundibulopelvic (IP) vein injury. Perioperative complications within 30 days after surgery were reported. In the LAS group, there was a case of pelvic pain and it was spontaneous regression. In the laparoscopic group, 3 cases of vaginal bleeding were reported. In the laparotomic group, 2 cases of vaginal bleeding and 2 cases of ileal bleeding were reported. The reported cases of complications related to vaginal bleeding were limited to those with symptoms that led to their re-admission after discharge.

Table 1 Patient demographics

Preoperative characteristics	LAS (n=25)	Laparoscopic (n = 82)	Laparotomic (n=170)	P value (compared laparoscopic with LAS)	P value (compared laparotomic with LAS)
Age (years, mean ± SD†) [range]	40.4±4.5 [33-51]	40.7±4.6 [32-52]	38.4±4.9 [24-65]	0.80	0.06
BMI (kg/m^2, mean ± SD) [range]	23.8±4.8 [16.43-32.59]	23.8±4.0 [17.78-42.23]	24.1±4.1 [17.15-40.35]	0.94	0.80
Parity (n, mean ± SD) [range]	1.3±1.0 [0-3]	1.6±0.9 [0-4]	0.6±0.8 [0-3]	0.29	0.00*
History of previous abdominal surgery (n (%))	12 (48.0)	42 (51.2)	80 (47.1)	0.78	0.93

† SD, Standard deviation; Data are expressed as the mean ± standard deviation or absolute number (percentage (%))

* Values are statistically significant ($p < 0.05$)

Table 2 Disease characteristics

Preoperative characteristics	LAS (n=25)	Laparoscopic (n = 82)	Laparotomic (n=170)	P value (compared laparoscopic with LAS)	P value (compared laparotomic with LAS)
Adenomyosis size: long diameter on USG (cm, mean ± SD†)	5.8±1.9 [3.5-10.8]	4.9±4.6 [2.2-44.0]	6.8±1.9 [2.3-12.7]	0.00*	0.01*
Indication of surgery (n (%))					
Menorrhagia	7 (28.0)	26 (31.7)	22 (12.9)		
Dysmenorrhea	3 (12.0)	21 (25.6)	47 (27.6)		
Combined symptom (Menorrhagia, Dysmenorrhea)	12 (48.0)	7 (8.5)	31 (18.2)	0.00*	0.00*
Recurrent spontaneous abortion	3 (12.0)	2 (2.4)	31 (18.2)		
Other	0 (0.0)	13 (15.9)	28 (16.5)		
Not documented	0 (0.0)	13 (15.9)	11 (6.5)		
Site of adenomyosis (n (%))					
Focal	14 (56.0)	78 (95.1)	80 (47.3)	0.00*	0.42
Diffuse	11 (44.0)	4 (4.9)	89 (52.7)		

† SD, Standard deviation; Data are expressed as the mean ± standard deviation or absolute numbers (percentage (%))

* Values are statistically significant ($p < 0.05$)

Table 3 Intraoperative outcome

Characteristics	LAS (n=25)	Laparoscopic (n=82)	Laparotomic (n=170)	P value (compared laparoscopic with LAS)	P value (compared laparotomic with LAS)
Incision length of LAS site (about)	Suprapubic: 4-6 cm, 2-port, umbilicus, left lower quadrant): 0.5-1 cm	0.5 – 1 cm (3-4 port)	10 - 14		
Combined operation (n (%))	17 (68.0)	39 (47.6)	79 (46.5)	0.07	0.04*
Pelvic adhesiolysis	8 (32.0)	13 (15.9)	32 (18.8)	0.09	0.13
EMS stages 1-2	3 (12.0)	4 (4.9)	7 (4.1)	0.35	0.12
EMS stages 3-4	6 (24.0)	4 (4.9)	16 (9.4)	0.01*	0.04*
Myomectomy	8 (32.0)	16 (19.5)	23 (13.5)	0.19	0.04*
Other‡	9 (36.0)	17 (20.7)	37 (21.8)	0.12	0.12
Combined uterine artery operation (n (%))					
BUAL§	18 (72.0)	2 (2.4)	1 (0.6)	0.00*	0.00*
TOUA‖	5 (20.0)	73 (89.0)	157 (92.4)		
Mass size					
Long diameter on pathology report (cm, mean ± SD†) [range]	7.2±3.4 [2.8-17.0]	5.9±2.6 [1.3-14.0]	7.43±2.73 [1.5-18.2]	0.11	0.23
Mass weight¶ (g, mean ± SD) [range]	85.5±71.7 [5.0-300.0]	39.3±25.9 [2.0-150.0]	108.2±91.9 [3.0-550.0]	0.00*	0.39
Intraoperative complication (n (%))					

Transfusion intraoperative	1 (4.0)	0 (0.0)	8 (4.7)	0.23	0.24
Others	0 (0.0)	0 (0.0)	3 (1.8) ††		
Operation time (min, mean ± SD) [range]	179.8±36.6 [100.0-255.0]	99.9±40.6 [60.0-255.0]	133.0±41.1 [75.0-395.0]	0.00*	0.00*
Estimated blood loss (ml, mean ± SD) [range]	208.0±128.8 [50.0-500.0]	119.5±79.6 [30.0-500.0]	193.6±193.0 [20.0-1000.0]	0.01*	0.11

† SD, Standard deviation; Data are expressed as the mean ± standard deviation or absolute numbers (percentage (%))

‡ Other combined operations, including surgeries, TCIC (transabdominal cervicoisthmic cerclage), salpingectomy, endometrial mass excision, paratubal mass removal.

§ BUAL, bilateral uterine artery ligation.

|| TOUA, transient occlusion uterine artery.

¶ Weight of 79 specimens of laparoscopic group, 169 specimens in laparotomic group and 25 specimens in HALS group, which were all cases that were reported.

†† 2 of uterine vein injury, 1 of IP vein injury.

* Values are statistically significant ($p < 0.05$).

Table 4 Postoperative outcomes

Characteristics	LAS (n=25)	Laparoscopic (n=82)	Laparotomic (n=170)	P value (compared laparoscopic with LAS)	P value (compared laparotomic with LAS)
Postoperative hemoglobin decline‡ (g/dl, mean± SD†) [range]	1.82±1.17 [0.10-4.20]	1.69±0.89 [0.00-4.20]	2.18±1.11 [0.20-6.10]	0.73	0.14
Postoperative transfusion (n (%))	1 (4.0)	0 (0.0)	8 (4.7)	0.23	1.00
Febrile morbidity§ (n (%))	6 (24.0)	2 (2.4)	26 (15.3)	0.00*	0.26
18 hours after surgery	6 (24.0)	2 (2.4)	26 (15.3)	0.00*	0.26
Perioperative complication within 30 days (n (%))	1 (4.0) ‖	3 (3.7) ¶	4 (2.4) ††	1.00	0.50
Postoperative hospital stay (day, mean ± SD) [range]	4.5±1.0 [3.0-7.0]	3.6±0.8 [2.0-6.0]	4.7±0.8 [3.0-8.0]	0.00*	0.27

† SD, Standard deviation; Data are expressed as the mean ± standard deviation or absolute numbers (percentage (%))

‡ Hemoglobin change between most recent preoperative hemoglobin and hemoglobin on postoperative day 1

§ Body temperature ≥ 37.8℃ after surgery

‖ Pelvic pain after discharge

¶ 3 of vaginal bleeding

†† 2 of vaginal bleeding, 2 of ileal bleeding

* Values are statistically significant ($p < 0.05$)

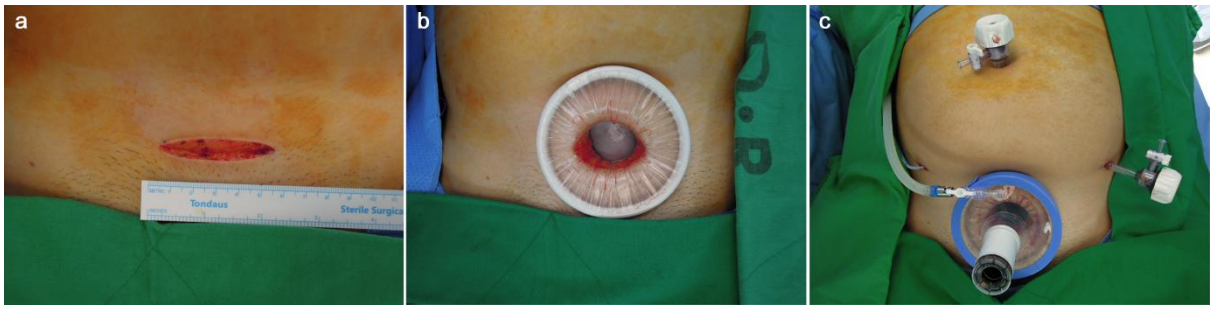

Figure 1 LAPAROSCOPIC-ASSISTED SURGERY site formation

1a. Mini-laparotomic incision (approximately 5 cm).

1b. Surgical retractor® insertion through the LAPAROSCOPIC-ASSISTED SURGERY site.

1c. The 5-mm trocar insertions were performed through the umbilicus and anti-McBurney's point.

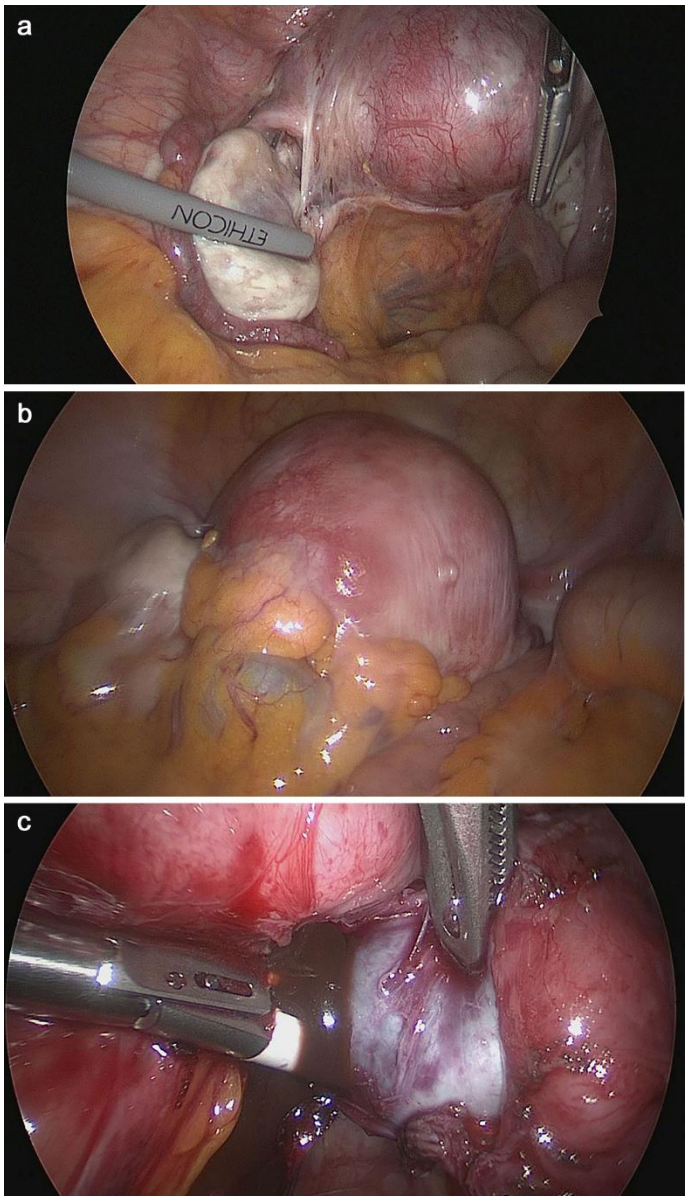

Figure 2 Preoperative findings

Adhesiolysis (preoperative adhesion; 2a, 2b) or adnexal surgery (endometrioma; 2c) was performed using a laparoscopic approach before adenomyomectomy.

Figure 2a, 2b. Preoperative adhesion.

Figure 2c. Endometrioma.

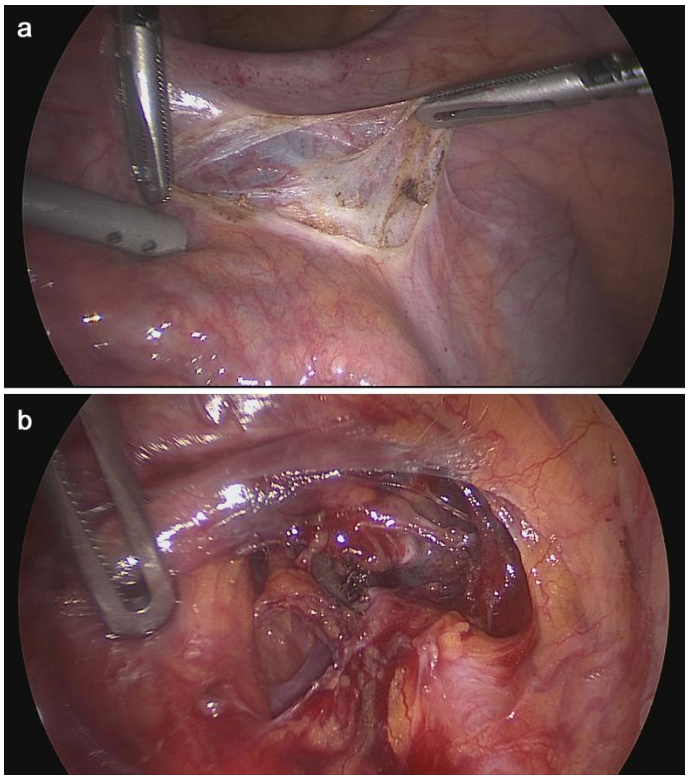

Figure 3 Laparoscopic bilateral uterine artery ligation (BUAL)

Manipulation of uterine artery in the laparoscopic approach

3a. Window between round ligament and mesosalpinx (Rt side of the patient).

3b. After completion of the uterine artery (Rt side of the patient).

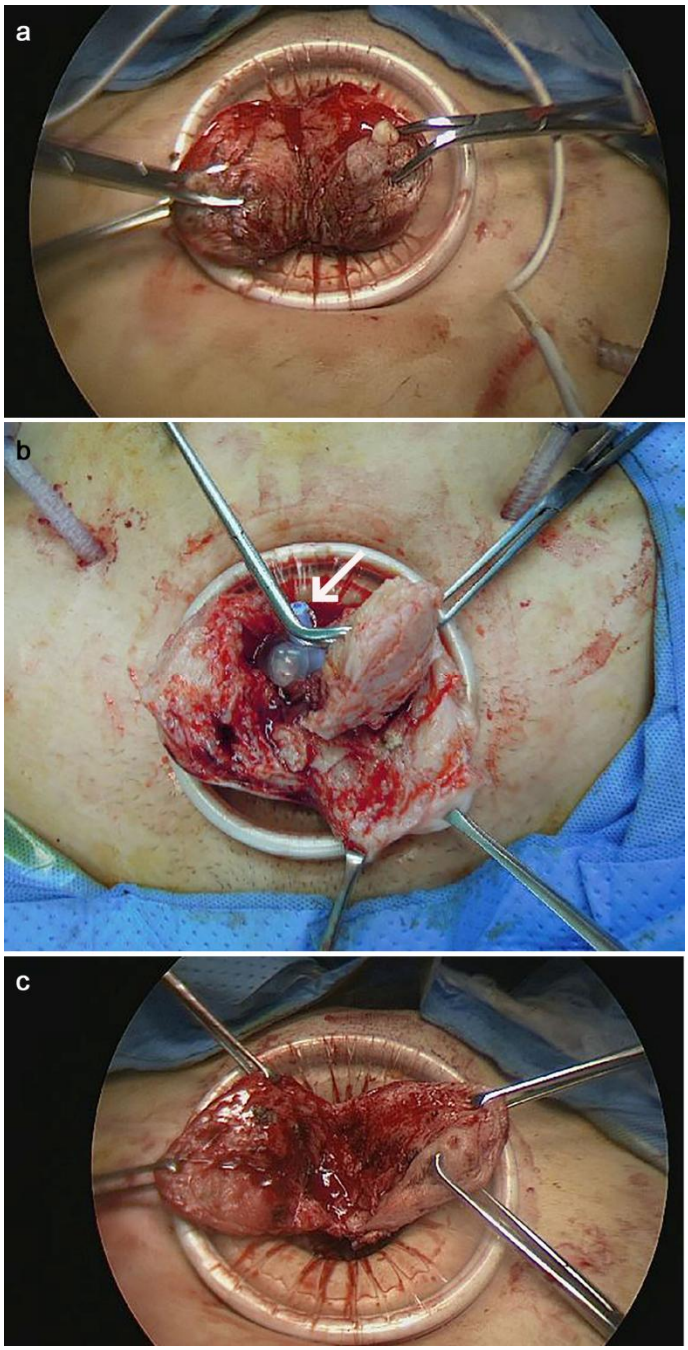

Figure 4 Exteriorization of the uterus and extracorporeal adenomyosis

4a. Sagittal incision of uterus.

4b. Removal of adenomyosis by scalpel; white arrow indicates uterine manipulator in endometrium.

4c. After removal of adenomyosis.

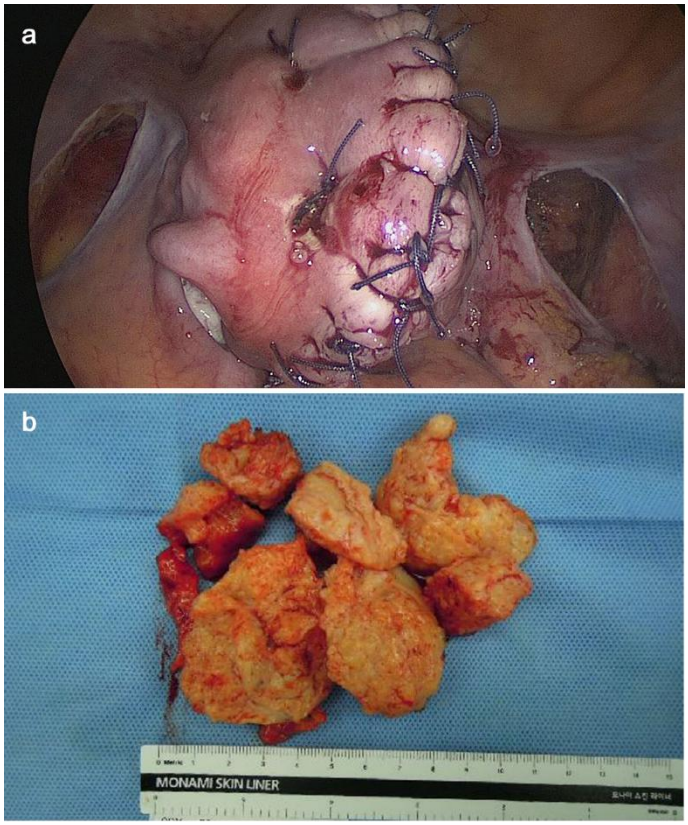

Figure 5 After the uterus was remodeled, it was returned to the peritoneal cavity

5a. Uterus after suturing in laparoscopic view.

5b. Removed mass.

Discussion

The treatment of adenomyosis symptoms, such as dysmenorrhea, pelvic pain or severe bleeding, affects the daily activities of patients [5]. Medical treatment is usually the first choice and includes treatment with progestins, intrauterine devices with levonorgestrel, GnRH agonists, and combined oral contraceptives [6]. However, surgery is considered for patients with medical treatment failure [6,7]. For those who desire uterine preservation, conservative surgery for uterine adenomyosis is considered. There is no standard for conservative surgical treatment of adenomyosis.

Kwack et al found that the laparoscopic approach and laparotomic approach were effective in focal adenomyomectomy. However, diffuse adenomyomectomy was not effective due to difficulties with the laparoscopic approach for maximal debulking and reconstruction of the uterus [3]. Furthermore, Zhu et al showed that laparotomic adenomyomectomy was superior to the laparoscopic approach in terms of curative effect and recurrence rate [8]. Osada et al reported that the laparoscopic approach might increase the risk of uterine rupture in subsequent pregnancy compared with laparotomic surgery [4,9].

For conservative adenomyosis surgery, efforts have been made to reduce blood loss during surgery. Reducing blood loss during surgery helps patients recover after surgery. Additionally, bleeding control provides a clear view of the operation field, consequently making it easier to locate the adenomyotic tissue and its border with the endometrium. Therefore, it is helpful for endometrial conservation and thus for fertility conservation. TOUA and BUAL are methods that have been proposed to reduce blood loss and to secure better operation field during surgery [10]. Indeed, adenomyomectomy combined with bilateral uterine artery ligation was reported to be an effective treatment for

symptomatic adenomyosis patients who desire uterine preservation [11,12], and the recurrence rate was lower after the BUAL procedure [12]. Additionally, uterine artery embolization and uterine artery occlusion/ligation are treatments for heavy menstrual bleeding [13,14]. However, for these manipulations of the uterine artery in the laparotomic approach, the surgeon usually needs a larger incision. The laparoscopic approach provides better visualization of uterine vessels and better exposure of the pelvic wall [15].

In these respects, LAS adenomyomectomy has strengths compared with laparoscopic or laparotomic adenomyomectomy, since LAS provides both laparoscopic and laparotomic approaches and has a smaller incision (approximately 5 cm, Table 3) than laparotomic surgery (10-14 cm).

In the present study, we proposed the LAS approach to adenomyomectomy. LAS adenomyomectomy had similar surgical outcomes to those of the laparotomic approach. Specifically, the median removed adenomyosis weights were comparable with laparotomic group and heavier than laparoscopic group. The even higher combined surgery rate (severe EMS and myoma, Table 3), number of hospital days and level of intraoperative blood loss were comparable with those in the laparotomic group. There were no complications, including vessel injury, vaginal bleeding after discharge or ileal bleeding, in the LAS group, but they were reported in the laparoscopic and/or laparotomic groups (Tables 3 and 4). However, the LAS group had a longer operation time than the other groups. In our opinion, this result was due to the following reasons. First, the LAS group had a higher rate of comorbid diseases. Second, the LAS procedure includes both abdominal cavity opening by mini laparotomic approach and laparoscopic approach with uterine artery manipulation. These hybrid procedures take more time than laparoscopic or laparotomic approache alone. Laparoscopic surgery had lower febrile morbidity than

LAS, but the rate of febrile morbidity was not different between the LAS and laparotomic groups. This result may be because those undergoing LAS surgery had extensive mass removal and remodeling, like the laparotomic approach, and because there were more cases of combined severe EMS surgery in the LAS group than in the laparoscopic group. However, there was a difference of one day in the median postoperative hospital stay, and there was no case of complications associated with fever after discharge.

An expert technique is needed for conservative adenomyomectomy, which is a burden for surgeons. This surgery requires more time than other benign surgeries and requires more delicate effort to remove the mass and remodel the uterus. Adenomyosis is frequently combined with other pathologies, such as EMS (including adhesions) [16,17] and myoma [18,19]. We propose that LAS can provide an easier method for adenomyomectomy by permitting the use of both the laparoscopic and laparotomic approaches with mini-laparotomic incisions.

There were several limitations of this study. First, there was a relatively small number of patients in the LAS group. Second, there were no comparative long-term follow-up results of complications or surgical outcomes. Third, since this study is a retrospective study, it is not randomized and the number of patients between the comparison groups is not constant. Despite these limitations, this study has several strengths. First, to our knowledge, this is the first study to introduce details of the LAS adenomyomectomy procedure and the first study to compare surgical outcomes of the LAS group with those of the laparoscopic and laparotomic groups at the same time. Second, this study is that the surgical outcome and postoperative complications of relatively many cases of adenomyomectomy were compared.

LAS adenomyomectomy has dual advantages of laparoscopic and laparotomic procedures. The former is better for uterine artery procedure and the latter is better for

complete excision of adenomyosis and delicate suturing. Also, additional laparoscopic surgery for pelvic pathology such as endometriosis can easily be performed, and future studies in various designs are warranted.

References

[1] Donnez J, Donnez O, Dolmans MM. Introduction: uterine adenomyosis, another enigmatic disease of our time. Fertil Steril 2018;109:369-70.

[2] Lohle PNM, Higue D, Herbreteau D. Uterine artery embolisation in women with symptomatic adenomyosis. Presse Med 2019;48:435-9.

[3] Kwack JY, Im KS, Kwon YS. Conservative surgery of uterine adenomyosis via laparoscopic versus laparotomic approach in a single institution. J Obstet Gynaecol Res. 2018;44:1268-73.

[4] Osada H. Uterine adenomyosis and adenomyoma: the surgical approach. Fertil Steril 2018;109:406-17.

[5] Shim JI, Jo EH, Kim M, Kim MK, Kim ML, Yun BS, et al. A comparison of surgical outcomes between robot and laparoscopy-assisted adenomyomectomy. Medicine (Baltimore) 2019;98:e15466.

[6] Oliveira MAP, Crispi CP, Jr., Brollo LC, Crispi CP, De Wilde RL. Surgery in adenomyosis. Arch Gynecol Obstet 2018;297:581-9.

[7] Dueholm M. Minimally invasive treatment of adenomyosis. Best Pract Res

Clin Obstet Gynaecol 2018;51:119-37.

[8] Zhu L, Chen S, Che X, Xu P, Huang X, Zhang X. Comparisons of the efficacy and recurrence of adenomyomectomy for severe uterine diffuse adenomyosis via laparotomy versus laparoscopy: a long-term result in a single institution. J Pain Res 2019;12:1917-24.

[9] Osada H, Silber S, Kakinuma T, Nagaishi M, Kato K, Kato O. Surgical procedure to conserve the uterus for future pregnancy in patients suffering from massive adenomyosis. Reprod Biomed Online 2011;22:94-9.

[10] Kwon YS, Roh HJ, Ahn JW, Lee SH, Im KS. Transient occlusion of uterine arteries in laparoscopic uterine surgery. JSLS 2015;19:e2014 00189.

[11] Kang L, Gong J, Cheng Z, Dai H, Liping H. Clinical application and midterm results of laparoscopic partial resection of symptomatic adenomyosis combined with uterine artery occlusion. J Minim Invasive Gynecol 2009;16:169-73.

[12] Liu M, Cheng Z, Dai H, Qu X, Kang L. Long-term efficacy and quality of life associated with laparoscopic bilateral uterine artery occlusion plus partial resection of symptomatic adenomyosis. Eur J Obstet Gynecol Reprod Biol

2014;176:20-4.

[13] Hassanin IM, Shahin AY, Abdel-Hafeez AT, Salem HT, El-Nashar SA. Bilateral uterine artery ligation via minilaparotomy for heavy menstrual bleeding. Int J Gynaecol Obstet 2008;103:222-6.

[14] Vilos GA, Vilos EC, Abu-Rafea B, Hollett-Caines J, Romano W. Transvaginal Doppler-guided uterine artery occlusion for the treatment of symptomatic fibroids: summary results from two pilot studies. J Obstet Gynaecol Can 2010;32:149-54.

[15] Di Furia M, Salvatorelli A, Della Penna A, et al. Advantage of laparoscopic resection for pelvic Schwannoma: case report and review of the literature. Int J Surg Case Rep 2018;45:38-41.

[16] Di Donato N, Montanari G, Benfenati A, et al. Prevalence of adenomyosis in women undergoing surgery for endometriosis. Eur J Obstet Gynecol Reprod Biol 2014;181:289-93.

[17] Donnez J, Dolmans MM, Fellah L. What if deep endometriotic nodules and uterine adenomyosis were actually two forms of the same disease? Fertil Steril 2019;111:454-6.

[18] Brucker SY, Huebner M, Wallwiener M, et al. Clinical characteristics indicating adenomyosis coexisting with leiomyomas: a retrospective, questionnaire-based study. Fertil Steril 2014;101:237-41 e231.

[19] Taran FA, Stewart EA, Brucker S. Adenomyosis: epidemiology, risk factors, clinical phenotype and surgical and interventional alternatives to hysterectomy. Geburtshilfe Frauenheilkd 2013;73:924-31.

국문 요약

복강경 이용 자궁선근증 절제술을 복강경 혹은 개복 자궁선근증 절제술과 비교하여 복강경 이용 자궁선근증 절제술의 안정성 및 장점을 확인하기 위함이 본 논문의 목적이다.

본 논문은 후향적 연구이며, 2016년 1월부터 2019년1월까지 울산대학교병원 산부인과에서 자궁선근증 절제술을 받은 총 277명의 환자들을 연구하였다. 이중 25명은 복강경 이용 자궁선근증 절제술(Laparostopic assisted adenomyomectomy, LAS)을 시행하였고, 82명은 복강경 자궁 선근증 절제술(laparoscopic adenomyomectomy), 170명은 개복 자궁 선근증 절제술(laparotomic adenomyomectomy)을 받았다. 복강경 이용 자궁선근증 절제술은 복강경 자궁 동맥의 시술과 미세절개개복술(mini-laparotomic)을 이용한 자궁선근증 절제술로 이루어 진다. 또한, 동반된 다른 골반 질환에 대해 추가적인 복강경 수술도 가능하다.

환자 인구통계(patients dermographics), 수술 적응증, 수술 시간, 혈액 소모량(EBL), 단기 합병증, 수술 후 입원기간이 비교되었다. 복강경 이용 수술(LAS)와 개복 수술(laparotomic group)은 혈액 소모량(EBL)(208.0±128.8 vs. 193.6±193.0 mL, p=0.11), 절제된 자궁 선근증의 무게(85.5±71.7 vs. 108.2±91.9 g, p=0.39), 그리고 수술 후 입원기간(HDs) (4.5±1.0 vs. 4.7±0.8 days, p=0.27)에 있어서 큰 차이를 보이지 않았다. 자궁근종 절제술 및 동반된 중증 자궁내막증을 포함한 추가적인 시술은 복강경 이용 수술(LAS)에서 개복(laparotomic group)수술 보다 더 많았다. 평균 수술 시간은 복강경 이용 수술(LAS)에서 (179.8±36.6 min) 다른 그룹들(laparoscopy 99.9±40.6 min, p<0.00; laparotomy 133.0±41.1 min, p<0.00)에 비해 더 길었다. 세 그룹은 수혈, 헤모글로빈 수치 변화, 수술 후 합병증이란 측면에서 특별한 차이를 보이지 않았다. 하

지만 수술 후 발열은 복강경 이용 수술(LAS) 혹은 개복(laparotomic group)수술 보다 복강경(laparoscopic group) 수술에서 더 낮았다.

복강경 이용 자궁선근증 절제술(LAS)은 복강경과 미세절개개복술을 통해 자궁선근증을 최대한 절제하기에 용이하다. 또한 이 접근법을 이용하면 양성 자궁과 난소의 동반된 질환도 쉽게 수술을 할 수 있는 이점이 있다.

중심단어 : 자궁선근증, 복강경 이용 수술, 미세절개개복술