[UCI]I804:48009-200000006655

석사학위논문

백서의 천공지 피판에서 혈관경의 회전이 피판의 혈액순환 및 생존에 미치는 영향

The Effect of Pedicle Rotation Direction on the Perfusion and Survival of Perforator Flaps in Rats

울산대학교 대 학 원
의 학 과
이 연 훈

백서의 천공지 피판에서 혈관경의 회전이 피판의 혈액순환 및 생존에 미치는 영향

지 도 교 수 홍 준 표

이 논문을 의학석사학위 논문으로 제출함

2017년 12월

울산대학교 대 학 원
의 학 과
이 연 훈

이 연 훈의 석사학위 논문을 인준함

심사위원 최 종 우 인

심사위원 홍 준 표 인

심사위원 서 현 석 인

울 산 대 학 교 대 학 원

2017년 12월

국문요약

서론

프로펠러 피판은 안정적인 혈관경을 가지며, 피판의 유동과 회전의 범위가 넓다. 혈관경 회전의 방향은 피판의 근위부 장축과 결손 부위 간의 각도에 따라 달라진다. 프로펠러 피판의 혈관경 수, 길이, 피판의 회전 각도의 크기에 대해서는 이전에 연구된 바가 있으나, 피판 회전의 방향 (우측 또는 좌측 방향)을 고려한 연구는 아직까지 이루어지지 않았다. 본 연구에서 저자는 피판의 회전에 유리함과 불리함의 개념이 존재한다는 가정 하에, 프로펠러 피판에서 피판 회전의 방향이 피판의 혈액순환 및 생존에 미치는 영향에 대하여 백서의 상복벽동맥천공지피판을 이용하여 분석하였다.

연구재료 및 연구방법

20마리의 9주령 Sprague-Dawley 백서가 본 연구에 포함되었다. 4 * 4 cm 크기의 사각형 피판을 복부에 디자인하였다. 천공지피판이 거상된 이후에, 피판의 표면에서 PeriScan PIM System®을 이용하여 평균순환량을 확인하였다. 이때 한 피판에서 회전을 가하지 않은 상태, 우측으로 90도 회전한 상태, 우측으로 180도 회전한 상태, 좌측으로 90도 회전한 상태, 좌측으로 180도

회전한 상태의 총 5가지 상황에서 평균순환량을 확인하였다. 이후 10마리의 백서에서는 피판을 유리한 방향으로 180도 회전시킨 후 고정하였고, 다른 10마리의 백서에서는 피판을 불리한 방향으로 180도 회전시킨 후 고정하였다. 피판의 생존에 대해서 inSight®를 이용하여 수술 후 7일째에 확인하였다. 혈관구조의 변화를 알아보기 위하여 혈관경의 중간 부위에서 광학현미경을 이용한 조직학적 분석을 시행하였다.

결과

90도 회전된 피판군에서 평균순환량은 43.75±10.29였고, 180도 회전된 피판군에서 평균순환량은 33.96±10.31이었다. 두 군 간의 차이는 통계학적으로 유의하였다. 유리한 방향으로 회전된 피판군에서 평균순환량은 37.84±10.64이었고, 불리한 방향으로 회전된 피판군에서 평균순환량은 30.08±8.55이었다. 유리한 방향으로 회전된 피판군에서 평균피판생존률은 90.4±7.1%이었고, 불리한 방향으로 회전된 피판군에서 평균피판생존률은 69.3±21.6%이었다. 두 군 간의 차이는 통계적으로 유의하였다. 조직학적 분석에서 불리한 방향으로 회전된 피판의 혈관경이 혈관주위 염증, 부종, 혈관신생 소견을 더 많이 보였다. 혈전 소견은 양 군에서 관찰되지 않았으며, 충혈 및 허혈 소견은 불리한 방향으로 회전된 피판의 혈관경에서 더 두드러지게

관찰되었다.

결론

본 연구에서 저자는 백서의 상복벽동맥천공지피판을 이용하여 혈관경 회전의 방향이 피판의 혈액순환 및 생존에 미치는 영향에 대하여 알아보았다. 혈관경 회전의 방향은 임상에서 피판 수술의 결과에 영향을 미치는 중요한 인자 중 하나로서 여겨져야 할 것이다. 혈관경의 불리한 방향 회전이 불가피한 상황에서는, 혈관경 주변 조직을 더 정리하는 방법을 권유한다.

중심단어

Perforator flap, Propeller flap, Pedicle, Rotation, Rat

목 차

표 및 그림 차례

Introduction

A flap is any tissue transfer that maintains its intrinsic circulation, from a basic pedicled flap to a free composite tissue transfer. The design of any flap must respect its vascular supply to ensure optimal viability.[1] The use of perforator flaps has increased since Koshima and Soeda[2] first introduced them. Perforator flaps offer the advantages of sparing the underlying muscle, resulting in decreased donor-site morbidity.

Hyakusoku[3] et al. first used the term 'propeller flap' in 1991, to describe two subcutaneous pedicled island flaps, vascularized by a perforator artery in the center and rotated 90°, for the reconstruction of skin scar contractures in burn patients. Propeller flaps have a reliable vascular pedicle and can undergo wide mobilization and rotation; their harvest is fast and easy and does not require microsurgery.[4] In 2006, combining the concept of propeller flaps and perforator based flaps, Hallock[5] reported a fasciocutaneous flap that was similar in shape to the one described by Hyakusoku[3] but was based on a skeletonized perforating vessel and was rotated 180° on an eccentric pivot point. The direction of rotation depends

on the angle between the proximal long axis of the flap and the defect. This angle can be maximum of 180°. It is not necessary to rotate the flap beyond 180° because it simply can be turned in the other direction.

According to previous reports, studies have been performed to investigate the number, length, and angle of rotation[6, 7] butt not on the direction of rotation (right or left). Based on the hypothesis that favorability of rotation direction exists in propeller flaps, we investigated the effect of rotation direction on the survival and circulation of flaps using a cranial epigastric artery perforator flap model in rats.[8] Furthermore, we suggested that rotation direction should be considered as an important clinical factor in propeller flaps besides the number, length, and angle of rotation.

Materials and Methods

Experimental procedures were reviewed and approved by the animal care and use committee of our institution, and we followed the Institutional and National Institute of Health guidelines for laboratory animal carel.

In total, 20 Sprague-Dawley rats aged 9 weeks were included in the study.

The rats were anesthetized using intraperitoneal injection of Alfaxan 30 mg/kg and Xylazine 10 mg/kg. After the abdominal area was shaved, the rats were fixed on an operating table in the supine position. A 4 cm × 4 cm rectangular flap was designed on the abdomen(Fig. 1).

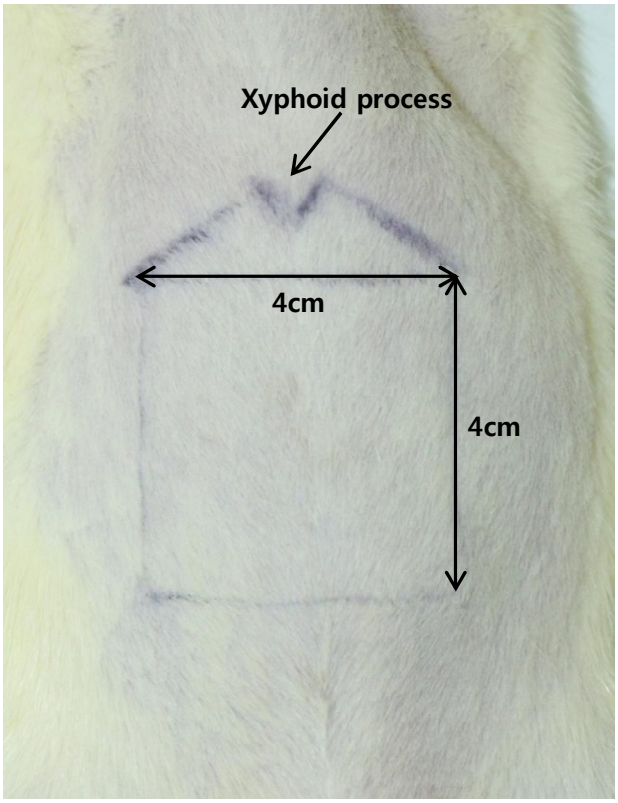

Fig. 1. Design of the cranial epigastric artery perforator flap.

Skin and panniculus carnosus were incised using a blade, and dissection was performed using blunt scissors. After perforators from the rectus muscle were noted, the most central and largest perforator was preserved while getting rid of other minor perforators. For standardization of its length, the

pedicle was skeletonized sparing the rectus fascia. Finally flaps based on a single cranial epigastric artery perforator were elevated(Fig. 2).

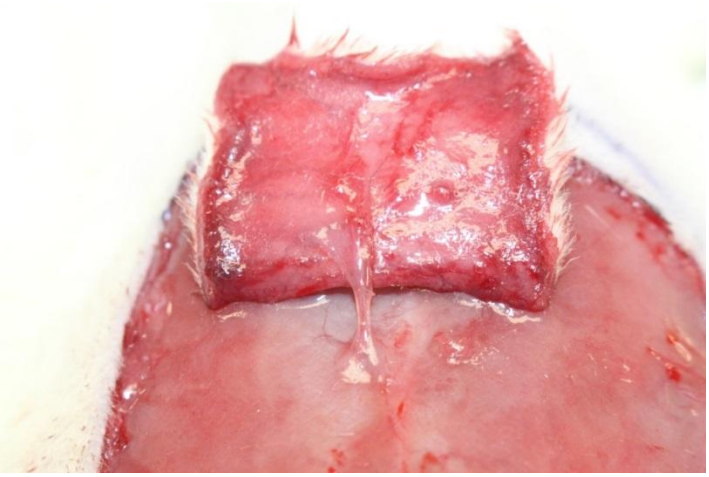

Fig. 2. Flap based on a single cranial epigastric artery perforator is elevated.

Once the perforator flap was elevated, we measured mean perfusion score on the flap surface using laser Doppler blood perfusion, imaging with the PeriScan PIM System® (Perimed AB, Järfälla, Stockholm, Sweden; Fig. 3) in five models: no, 90° right, 180° right, 90° left, and 180° left rotations(Fig. 4). The direction of rotation with the higher mean perfusion score was regarded as favorable rotation. The flap was inset with 180° favorable rotation in 10 rats and 180° unfavorable rotation in 10 rats(Fig. 5). The operative site was closed with using nonabsorbarble sutures, and intramuscular injection ketolorac 1 mg/kg and ampicillin 20 mg/kg were administered.

The viable flap area was checked using a three-dimensional digital wound assessment device (inSight®; eKare Inc., Fairfax, USA; Fig. 6) at seven days postoperatively. Using inSight®, the flap dimension was checked by drawing with the fingers, measuring the viable area and calculating the viable flap area ratio.

Histological analysis using a standard light microscopy was performed on the middle portion of pedicles to evaluate changes in vascular structure (edema, inflammation, congestion, and ischemia). The specimens were fixed using a neutral formalin solution with 10% buffer for two days, then dehydrated in alcohol and embedded in paraffin blocks. 5-μm sections were cut, deparaffinized, and stained with hematoxylin-eosin.

For statistical analysis, the independent-sample *t*-test was performed to evaluate the difference in mean perfusion score and flap survival using SAS software version 9.4 (SAS Institute, Cary, NC, USA). P values < 0.05 were considered to be significant.

Fig. 3. Laser Doppler blood perfusion imager, PeriScan PIM 3 System® (Perimed AB, Järfälla, Stockholm, Sweden)

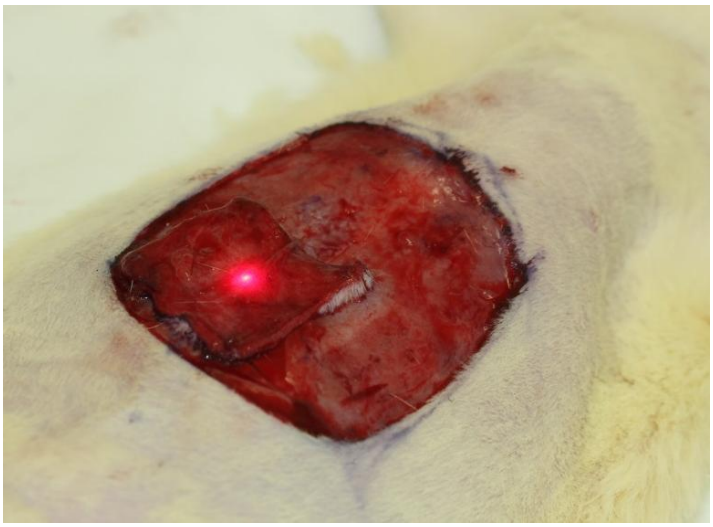

Fig. 4. Measuring mean perfusion score on flap surface using PeriScan PIM 3 System®

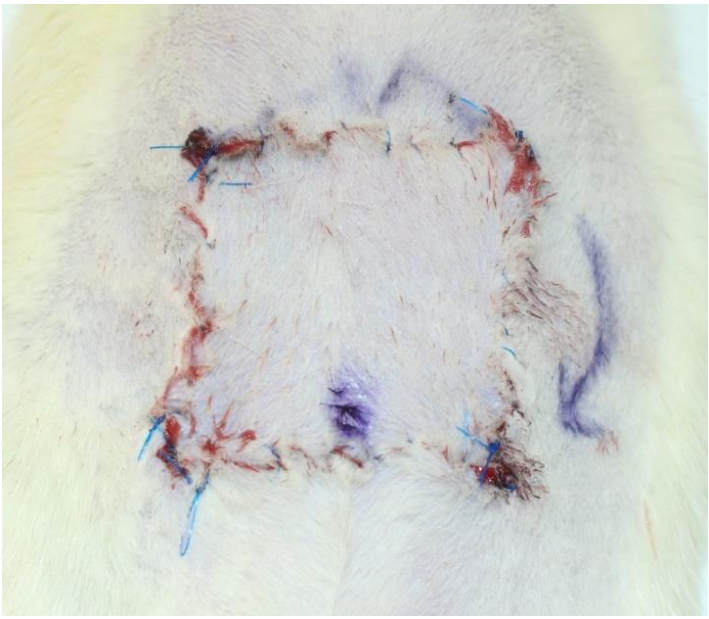

Fig. 5. Flap inset with nonabsorbable sutures.

Fig. 6. Three-dimensional digital wound assessment device, inSight® (eKare Inc., Fairfax, USA)

Results

Regardless of rotation favorability, mean perfusion score was compared between 90° and 180° rotation groups, and was 43.75 ± 10.29 and 33.96 ± 10.31. The difference between the groups was statistically significant(Table 1).

Table 1. Mean perfusion score of 90° rotation, 180° rotation group

	90° rotation (N = 40)	180° rotation (N = 40)	*p*
Mean perfusion score (Range±SD)	43.75 (24.05-72.20±10.29)	33.96 (14.63-60.22±10.31)	0.000

SD: Standard deviation

Mean perfusion score and viable flap area ratio were compared between the favorable and unfavorable rotation groups(37.84 ± 10.64 and 30.08 ± 8.55, respectively). Mean viable flap area ratio was 90.4 ± 7.1 and 69.3 ± 21.6, respectively. The mean perfusion and flap survival differences between the groups was significant(Table 2). The gross appearance of each group flaps at seven days postoperatively is shown in Figure 7.

Histological findings showed that the tendency for perivescular inflammation, edema, and neovascularization was greater in the unfavorable than in the favorable rotation groups. Thrombus was not noted in either group. Congestion and ischemia were obvious in the unfavorable rotation group(Fig. 8).

Table 2. Mean perfusion score and viable flap area ratio of favorable, unfavorable rotation group

	180° Favorable rotation (N=10)	180° Unfavorable rotation (N=10)	*p*
Mean perfusion score (Range±SD)	37.84 (23.35-60.22±10.64)	30.08 (14.63-44.74±8.55)	0.016
Mean viable flap area ratios (%, range±SD)	90.4 (82.2-100±7.1)	69.3 (34.9-100±21.6)	0.001

SD: Standard deviation

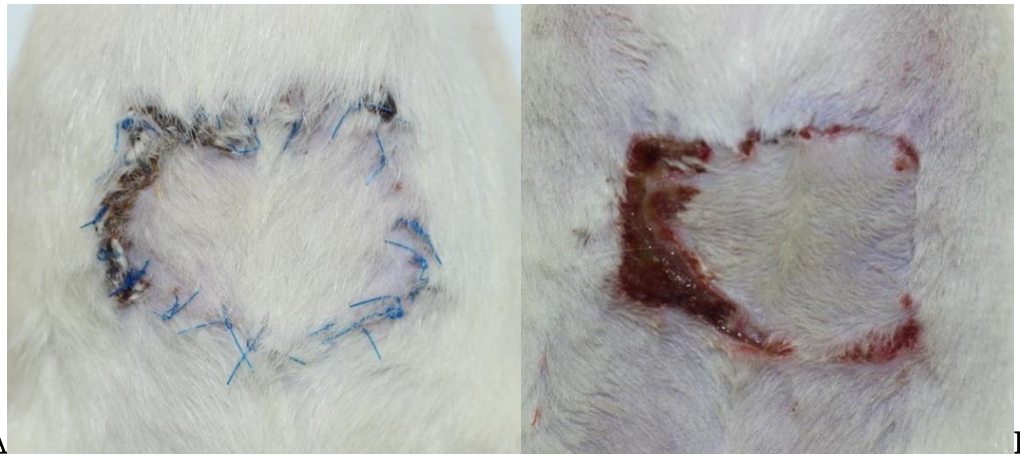

Fig. 7. Gross appearance of favorable (A), and unfavorable (B) rotation group flaps at seven days postoperatively

A 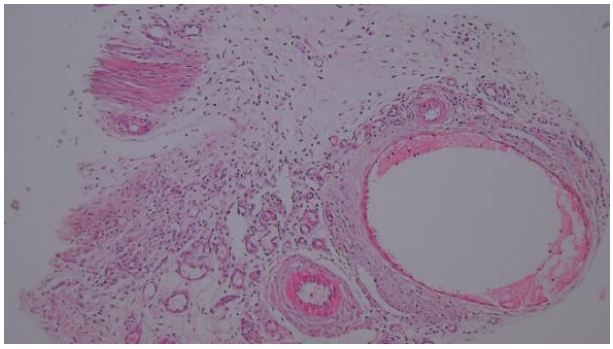

B 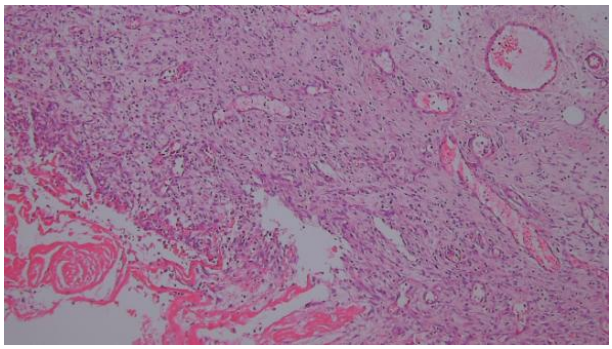

Fig. 8. Light microscopic findings of hematoxylin eosin-stained pedicles in favorable (A), unfavorable (B) rotation groups(original magnification×10)

Discussion

Despite improved understanding of the skin blood supply and advances in reconstructive techniques, flap failure remains a significant problem. The major cause of skin flap failure is insufficient arterial blood flow, but poor

venous outflow also may be responsible for inadequate perfusion and consequent flap failure. Both routes leading to flap failure may be because of factors, such as poor flap design, thrombosis of the vascular pedicle, kinking of the pedicle, hematoma formation, hypovolemia and hypotension, hyperviscosity, low hematocrit, hypothermia, and infection[9].

We did not work on the perforator flaps which were not rotated as a control group. Basically, the cranial epigastric artery perforator flap of the rat model has 100% flap survival without any rotation[8]. Although sample size was relatively small, our results showed significant difference in flap survival in the 180° rotation group, similar to the result of previous reports. Mean perfusion score was compared from the perspective of rotation angle and rotation favorability, the difference was larger in the aspect of rotation angle(9.79 vs. 7.75). With this outcome, we suggested that different factors affect the survival of flaps based on twisted perforators, and a higher level of pedicle twist mainly reduces flap viability[6].

Previous studies on pedicle torsion have focused mostly on its effect on microsurgical anastomosis. Torsion has been shown to slow down the blood stream by increasing the resistance in the vessel wall, to give rise to

endothelial damage by causing turbulent flow, and to lead to thrombus formation[10]. Torsion on an entire artery and vein does not restrict the blood flow, when the pedicle has adequate longitudinal space. A sufficient pedicle length will not create knot-like pressure in the inner structure of the pedicle itself. However, if the length is short, knot-like pressure will be created in the inner structure of the artery and vein, collapsing the lumens of the vessels and restricting blood flow[9]. Therefore, in case of inevitable unfavorable pedicle rotation, further skeletonization and division should be performed to increase flap survival.

In histological analysis of previous reports, luminal collapse of vein, perivascular inflammation, and endothelial damage were more severe with a larger angle of rotation[7]. In our study, the tendency for perivescular inflammation, edema, and neovascularization was greater in unfavorable than in favorable rotation group pedicles. Thrombus was not found in either group. Congestion and ischemia was obvious in the unfavorable rotation group.

In a previous clinical report, complication rates were higher in flaps with the arc of rotation between 150° and 180° with marginal significance compared to flaps with the arc of rotation less than 150°[11]. Similar clinical

investigation was done at our institution, and the existence of rotation favorability was proved using duplex ultrasonography. Flap survival by favorability of rotation could not be evaluated because of ethical issues. Actually, Schonauer et al.[12] suggested the flap inset method considering the favorability of rotation; that is, try both right and left rotations, and then choose the rotation direction that presents better perfusion.

Prediction of rotation favorability preoperatively would be helpful for flap design. However, we were not able to determine the specific mechanism to predict favorability of rotation in perforator-based propeller flaps. Further researches with larger sample size assessing various factors should be performed to reveal the specific mechanism of rotation favorability.

Conclusion

In this study, we determined the effect of pedicle rotation direction on perfusion and survival of perforator flaps in a rat model. Rotation direction should be considered as an important factor affecting flap outcomes in clinical situations, and we recommend further division of the pedicle as a

solution in case of inevitable unfavorable pedicel rotation.

References

1. Maciel-Miranda, A., S.F. Morris, and G.G. Hallock, *Local flaps, including pedicled perforator flaps: anatomy, technique, and applications.* Plast Reconstr Surg, 2013. 131(6): p. 896e-911e.
2. Yu, S., et al., *Perforator Propeller Flap for Oncologic Reconstruction of Soft Tissue Defects in Trunk and Extremities.* Ann Plast Surg, 2016. 77(4): p. 456-63.
3. Sisti, A., et al., *Propeller Flaps: A Literature Review.* In Vivo, 2016. 30(4): p. 351-73.
4. D'Arpa, S., et al., *Propeller flaps: a review of indications, technique, and results.* Biomed Res Int, 2014. 2014: p. 986829.
5. Teo, T.C., *The propeller flap concept.* Clin Plast Surg, 2010. 37(4): p. 615-26, vi.
6. Demir, A., et al., *The effect of twisting on perforator flap viability: an experimental study in rats.* Ann Plast Surg, 2006. 56(2): p. 186-9.
7. Chang, C.H., et al., *The influence of pedicle length on the viability of twisted perforator flaps in rats.* J Reconstr Microsurg, 2009. 25(9): p. 533-8.
8. Hallock, G.G. and D.C. Rice, *Cranial epigastric perforator flap: a rat model of a true perforator flap.* Ann Plast Surg, 2003. 50(4): p. 393-7.
9. Gokrem, S., et al., *Effects of 360-degree pedicle torsion on island skin flaps: experimental study in rats.* J Reconstr Microsurg, 2005. 21(5): p. 313-6.
10. Bektas, G., et al., *Comparing the effects of pedicle torsion on axial or perforator flaps; improving the perforator flap resistance to pedicle*

torsion with delay phenomenon. J Reconstr Microsurg, 2014. 30(8): p. 531-8.

11. Paik, J.M. and J.K. Pyon, *Risk Factor Analysis of Freestyle Propeller Flaps.* J Reconstr Microsurg, 2017. 33(1): p. 26-31.
12. Schonauer, F., et al., *Choosing the correct sense of rotation in 180 degrees propeller flaps.* J Plast Reconstr Aesthet Surg, 2008. 61(12): p. 1492.

Abstract

Background

Propeller flaps have a reliable vascular pedicle and can undergo wide mobilization and rotation. The direction of rotation depends on the angle between the proximal long axis of the flap and the defect. Based on the hypothesis that favorability of rotation direction exists in the propeller flap, we investigated the effect of rotation direction on survival and circulation of flaps using a cranial epigastric artery perforator flap model in rats.

Methods

We studied 20 Sprague-Dawley rats aged 9 weeks. A 4 × 4 cm rectangular flap was designed on the abdomen. Once the perforator flap was elevated, we measured mean perfusion score on the flap surface using laser Doppler blood perfusion imaging in five models: no, 90° right, 180° clockwise, 90° left, and 180° left rotations. The flap was inset with 180° favorable rotation in 10 rats and 180° unfavorable rotation in 10. Viable flap area was checked with a three-dimensional digital wound assessment device at seven days postoperatively. Histological analysis with a standard light microscope was

done on the middle portion of pedicles to evaluate changes in vascular structure (edema, inflammation, congestion, and ischemia).

Results

Mean perfusion scores were 43.75 ± 10.29 and 33.96 ± 10.31 in the 90° and 180° rotation groups, respectively (statistically significant difference), and 37.84 ± 10.64 and 30.08 ± 8.55 in the favorable and unfavorable rotation groups, respectively. Mean viable flap area ratios were 90.4% ± 7.1% and 69.3% ± 21.6%, respectively. Mean perfusion and flap survival differences between the groups were significant. Histological findings showed that perivascular inflammation, edema, and neovascularization were greater in the unfavorable than in the favorable rotation groups. Thrombus was not found in either group. Congestion and ischemia were obvious in the unfavorable rotation group.

Conclusion

With abdominal perforator-based propeller flaps in a rat model, we demonstrated the effect of pedicle rotation direction on perfusion and survival of perforator flaps. Rotation direction should be an important factor

affecting flap outcomes in clinical situations. We recommend further division of the pedicle as a solution in case of inevitable unfavorable pedicle rotation.

Keywords

Perforator flap, Propeller flap, Pedicle, Rotation, Rat